An Official American Thoracic Society Clinical Practice Guideline: The Clinical Utility of Bronchoalveolar Lavage Cellular Analysis in Interstitial Lung Disease

Keith C. Meyer, Ganesh Raghu, Robert P. Baughman, Kevin K. Brown, Ulrich Costabel, Roland M. du Bois, Marjolein Drent, Patricia L. Haslam, Dong Soon Kim, Sonoko Nagai, Paola Rottoli, Cesare Saltini, Moisés Selman, Charlie Strange, and Brent Wood, on behalf of the American Thoracic Society Committee on BAL in Interstitial Lung Disease

THIS OFFICIAL CLINICAL PRACTICE GUIDELINE OF THE AMERICAN THORACIC SOCIETY (ATS) WAS APPROVED BY THE ATS BOARD OF DIRECTORS, JANUARY 2012

CONTENTS

Executive Summary
Introduction
Methods
BAL Cellular Analyses as a Diagnostic Intervention for Patients with Suspected ILD in the Era of HRCT Imaging
Performing, Handling, and Processing BAL
Pre-Procedure Preparation
The BAL Procedure
Handling of the BAL Fluid
Processing
BAL Cellular Analysis in the Diagnosis of Specific ILD
Technique of BAL Cell Analyses
Interpretation of BAL Differential Cell Counts
Conclusions and future directions

***Background*: The clinical utility of bronchoalveolar lavage fluid (BAL) cell analysis for the diagnosis and management of patients with interstitial lung disease (ILD) has been a subject of debate and controversy. The American Thoracic Society (ATS) sponsored a committee of international experts to examine all relevant literature on BAL in ILD and provide recommendations concerning the use of BAL in the diagnosis and management of patients with suspected ILD.**
***Purpose*: To provide recommendations for (*1*) the performance and processing of BAL and (*2*) the interpretation of BAL nucleated immune cell patterns and other BAL characteristics in patients with suspected ILD.**
***Methods*: A pragmatic systematic review was performed to identify unique citations related to BAL in patients with ILD that were published between 1970 and 2006. The search was updated during the guideline development process to include published literature through March 2011. This is the evidence upon which the committee's conclusions and recommendations are based.**
***Results*: Recommendations for the performance and processing of BAL, as well as the interpretation of BAL findings, were formulated by the committee.**
***Conclusions*: When used in conjunction with comprehensive clinical information and adequate thoracic imaging such as high-resolution computed tomography of the thorax, BAL cell patterns and other characteristics frequently provide useful information for the diagnostic evaluation of patients with suspected ILD.**

This article has an online supplement, which is accessible from this issue's table of contents at www.atsjournals.org

Am J Respir Crit Care Med Vol 185, Iss. 9, pp 1004–1014, May 1, 2012
Copyright © 2012 by the American Thoracic Society
DOI: 10.1164/rccm.201202-0320ST
Internet address: www.atsjournals.org

Keywords: bronchoscopy; bronchoalveolar lavage; lung diseases; interstitial lung disease; cell differential count

EXECUTIVE SUMMARY

In patients with interstitial lung disease (ILD), accurate interpretation of bronchoalveolar lavage (BAL) cellular analyses requires that the BAL be performed correctly and that the BAL fluid be handled and processed properly. Because there is a paucity of evidence from controlled clinical trials related to these steps and the clinical utility of BAL cellular analysis, the recommendations provided were informed largely by observational studies and the unsystematic observations of experts in the fields of BAL and ILD. It is our hope that these guidelines will increase the utility of BAL in the diagnostic evaluation of ILD and promote the use of BAL in clinical studies and trials of ILD so that future guidelines may be based upon higher quality evidence.

In the online supplement to these guidelines, we describe each of the following in detail: the technique for performing BAL; specimen handling, transport, and processing; gross analysis and differential cellular analysis; infection screening; flow cytometry; and using the BAL cellular findings narrow the differential diagnosis of ILD.

I. Conclusions

1. Following the initial clinical and radiographic evaluation of patients presenting with suspected ILD, BAL cellular analysis may be a useful adjunct in the diagnostic evaluation of individuals who lack a confident usual interstitial pneumonia (UIP) pattern on high-resolution computed tomography (HRCT) imaging of the thorax. Important considerations about whether to perform a BAL include the degree of uncertainty about the type of ILD, the likelihood that the BAL will provide helpful information, the patient's cardiopulmonary stability, the presence or absence of a bleeding diathesis, and the patient's values and preferences.
2. Recognition of a predominantly inflammatory cellular pattern (increased lymphocytes, eosinophils, or neutrophils) in the BAL differential cell profile frequently helps the clinician narrow the differential diagnosis of ILD, even though such patterns are nonspecific.
3. A normal BAL differential cell profile does not exclude microscopic abnormalities in the lung tissue.

4. BAL cellular analysis alone is insufficient to diagnose the specific type of ILD, except in malignancies and some rare ILDs. However, abnormal findings may support a specific diagnosis when considered in the context of the clinical and radiographic presentations.
5. BAL cellular analysis has no firmly established prognostic value and cannot predict the response to therapy.

II. Recommendations

1. For patients with suspected ILD in whom it has been decided that a BAL can be tolerated and will be performed, we suggest that the BAL target site be chosen on the basis of an HRCT performed before the procedure, rather than choosing a traditional BAL site (i.e., the right middle lobe or lingula). In our clinical practices, we perform the HRCT within 6 weeks of the BAL.
2. For patients with suspected ILD who undergo BAL, we recommend that a differential cell count be performed on the BAL fluid. This includes macrophage, lymphocyte, neutrophil, and eosinophil cell counts. The remaining sample may be used for microbiology, virology, and/or malignant cell cytology laboratory testing if clinically indicated.
3. For patients with suspected ILD in whom BAL is performed, we suggest that lymphocyte subset analysis NOT be a routine component of BAL cellular analysis.

III. Summary of the Procedure, Transport, Processing, and Analysis

1. BAL is performed with the fiberoptic bronchoscope in a wedge position within the selected bronchopulmonary segment. The total instilled volume of normal saline should be no less than 100 ml and should not exceed 300 ml. Three to five sequentially instilled aliquots are generally withdrawn after each aliquot instillation.
2. For optimal sampling of distal airspaces, the total volume (pooled aliquots) retrieved should be greater than or equal to 30% of the total instilled volume. A total volume of retrieved fluid less than 30% may provide a misleading-cell differential, especially if total retrieved volume is less than 10% of total instilled volume. If less than 5% of each instilled aliquot volume is recovered during the procedure due to retention of most of the fluid in the lavaged segment, the procedure should be aborted to avoid increased risk of tissue disruption and/or inflammatory mediator release due to overdistention of the lavaged segment.
3. A minimal volume of 5 ml of a pooled BAL sample is needed for BAL cellular analysis. The optimal volume is 10 to 20 ml. It is acceptable to pool all aliquots of the retrieved BAL fluid for routine analyses (including the first retrieved aliquot).
4. BAL cell differential counts with greater than 15% lymphocytes, greater than 3% neutrophils, greater than 1% eosinophils, and greater than 0.5% mast cells represent a lymphocytic cellular pattern, neutrophilic cellular pattern, eosinophilic cellular pattern, and mastocytosis, respectively. Each has diagnostic implications, as described within the Table 1.
5. A predominance of macrophages containing smoking-related inclusions with no or minor increases in other cell types is compatible with smoking-related ILD such as desquamative interstitial pneumonia (DIP), respiratory bronchiolitis interstitial lung disease (RBILD), and Langerhans cell histiocytosis.

INTRODUCTION

Acute and chronic bilateral parenchymal infiltrative lung diseases with variable degrees of tissue inflammation and fibrosis are collectively referred to as interstitial lung diseases (ILDs) when they occur in immunocompetent hosts without infection or neoplasm (1). ILDs are generally characterized clinically by exertional dyspnea, bilateral pulmonary infiltrates on thoracic imaging, abnormal pulmonary physiology, and abnormal gas transfer, while they are usually characterized pathologically by an accumulation of inflammatory and immune effector cells that is often accompanied by abnormal extracellular matrix in the distal airways, alveolar walls, and interstitium. The ILDs usually evolve over months to years and include disorders of both known and unknown cause. Among the ILDs with known causes or associations are the pneumoconioses, ILD associated with connective tissue disease (CTD-ILD), and hypersensitivity pneumonitis (HP). Among the ILDs of unknown cause are sarcoidosis and idiopathic interstitial pneumonias (IIP).

IIP is a term that encompasses a heterogeneous group of ILDs of unknown etiology (2). It includes idiopathic pulmonary fibrosis (IPF), nonspecific interstitial pneumonia (NSIP), desquamative interstitial pneumonia (DIP), respiratory bronchiolitis with interstitial lung disease (RBILD), acute interstitial pneumonia (AIP), cryptogenic organizing pneumonia (COP), and lymphoid interstitial pneumonia (LIP). In the appropriate clinical setting, IPF is a distinctive clinical entity characterized by the pattern of usual interstitial pneumonia (UIP) on high-resolution computed tomography (HRCT) imaging and/or surgical lung biopsy (2, 3). In the appropriate clinical setting it has been recommended that the recognition of precise radiologic and/or surgical lung biopsy characteristics is sufficient to make a specific diagnosis of IPF (4). Of interest is the finding that certain IIP pathologies may coexist in the same patient when multiple regions of the lung are biopsied, especially UIP and NSIP in patients with IPF (5). In addition, these lung pathology patterns also occur in other disorders such as connective tissue–associated ILD and thus are not disease-specific.

Although most forms of ILD are chronic, some rare forms of ILD can present acutely. Acute exacerbations of chronic ILD may also occur (6, 7). Examples of ILDs that may occur acutely include AIP, acute eosinophilic pneumonia (AEP), acute hypersensitivity pneumonitis (AHP), diffuse alveolar hemorrhage (DAH), COP, drug reactions, and acute exacerbations of IPF or other forms of ILD. The differential diagnosis of these disorders rests on the clinician's interpretation of the patient's clinical presentation, combined with physical examination, pulmonary physiologic testing, chest radiographic imaging, and sampling of lung tissue.

A number of previous statements have addressed the use of bronchoalveolar lavage (BAL) to evaluate patients with suspected ILD (8–12), but these were published prior to HRCT becoming a routine diagnostic tool and before the recognition of the IIPs as distinct clinical entities. This American Thoracic Society (ATS) clinical practice guideline provides a comprehensive, conceptually balanced, and evidence-based perspective on the clinical utility of BAL cellular analysis for the evaluation of suspected ILD. Because there is considerable variability in techniques used by pulmonologists and medical centers for performing and analyzing BAL worldwide, the committee also provides guidelines that we hope will facilitate the standardization of the BAL procedure, the handling and processing of BAL fluid, and the interpretation of findings. Finally, recommendations are made for future research.

TABLE 1. SUMMARY OF BAL CELLULAR PATTERNS IN NORMAL/HEALTHY ADULT NONSMOKERS AND IN PATIENTS WITH COMMON INTERSTITIAL LUNG DISEASES (CONSISTENT PATTERNS AND CLINICAL UTILITY)

I. Normal Adults (Nonsmokers)	BAL Differential Cell Counts
Alveolar macrophages	>85%
Lymphocytes (CD4+/CD8+ = 0.9–2.5)	10–15%
Neutrophils	⩽3%
Eosinophils	⩽1%
Squamous epithelial*/ciliated columnar epithelial cells†	⩽5%

II. Interstitial lung diseases

a. Disorders associated with increased percentage of specific BAL cell types

Lymphocytic cellular pattern	Eosinophilic cellular pattern	Neutrophilic cellular pattern
>15% lymphocytes	>1% eosinophils	>3% neutrophils
Sarcoidosis	Eosinophilic pneumonias	Collagen vascular diseases
Nonspecific interstitial pneumonia (NSIP)	Drug-induced pneumonitis	Idiopathic pulmonary fibrosis
Hypersensitivity pneumonitis	Bone marrow transplant	Aspiration pneumonia
Drug-induced pneumonitis	Asthma, bronchitis	Infection: bacterial, fungal
Collagen vascular diseases	Churg-Strauss syndrome	Bronchitis
Radiation pneumonitis	Allergic bronchopulmonary aspergillosis	Asbestosis
Cryptogenic organizing pneumonia (COP)	Bacterial, fungal, helminthic, *Pneumocystis* infection	Acute respiratory distress syndrome (ARDS)
Lymphoproliferative disorders	Hodgkin's disease	Diffuse alveolar damage (DAD)

b. Abnormal BAL differential cell patterns that suggest specific types of ILD

A lymphocyte differential count ⩾25% suggests granulomatous disease (sarcoidosis, hypersensitivity pneumonitis, or chronic beryllium disease), cellular nonspecific interstitial pneumonia, drug reaction, lymphoid interstitial pneumonia, cryptogenic organizing pneumonia, or lymphoma.
CD4+/CD8+ >4 is highly specific for sarcoidosis in the absence of an increased proportion of other inflammatory cell types.
A lymphocyte differential count >50% suggests hypersensitivity pneumonitis or cellular nonspecific interstitial pneumonia.
A neutrophil differential count >50% supports acute lung injury, aspiration pneumonia, or suppurative infection.
An eosinophil differential count >25% is virtually diagnostic of acute or chronic eosinophilic pneumonia.
A cell differential count of >1% mast cells, >50% lymphocytes, and >3% neutrophils is suggestive of acute hypersensitivity pneumonitis.

c. Other abnormal BAL findings

Infectious organism	Lower respiratory infection
Malignant cells (light microscopy, flow cytometry)	Cancer
Bloody fluid that increases in successive aliquots	Pulmonary hemorrhage ± diffuse alveolar damage
Milky fluid with positive periodic acid Schiff staining and amorphous debris	Pulmonary alveolar proteinosis
In vitro lymphocyte proliferative response to specific beryllium antigen	Chronic beryllium disease

Definition of abbreviation: BAL = bronchoalveolar lavage.
* The presence of squamous epithelial cells indicates upper airway secretion contamination.
† Epithelial cells > 5% suggest suboptimal sample (BAL cellular patterns should be interpreted with caution).

METHODS

The ATS *Ad Hoc* Committee on the clinical utility of BAL in ILD included an international group of experts with established, long-standing clinical and research expertise in ILD and BAL. The chairs were approved by the ATS, and the panel members were specifically selected by the chairs from established centers worldwide to review the existing literature and to answer clinical questions based upon the published evidence or, when such evidence was lacking, based upon prevailing knowledge and experience.

A pragmatic systematic review was performed by committee members and confirmed by the chairs. PubMed was used to search Medline for relevant publications (original articles, systematic reviews) in the English language from 1970 through March 2011. Prespecified primary search terms were "interstitial lung disease" AND "bronchoalveolar lavage," with additional search terms selected as appropriate for the clinical question (e.g., "AND lymphocyte subsets"). Relevant publications meeting prespecified selection criteria were selected by committee members, and the bibliographies of selected articles were reviewed for additional articles. Articles were excluded if the methods for performing BAL or obtaining differential cell counts could not be determined.

For clinical questions related to the technical aspects of BAL in ILD, discussion and consensus was used to derive conclusions and recommendations. In contrast, for clinical questions in which there was a well-defined intervention and reasonable alternative, a more systematic approach was used to appraise the evidence and to formulate the recommendations. Disagreements were resolved by discussion and consensus.

Generally speaking, controlled clinical trials for ILD provided little data related to BAL cellular analysis. Thus, most of the recommendations are based upon cross-sectional analyses, prospective and retrospective cohort studies, case series, and the clinical experience of the committee members. The methods used for this guideline are provided in Table 2.

BAL CELLULAR ANALYSES AS A DIAGNOSTIC INTERVENTION FOR PATIENTS WITH SUSPECTED ILD IN THE ERA OF HRCT IMAGING

HRCT can noninvasively identify specific imaging patterns that may be virtually diagnostic or strongly support certain forms of ILD. This has greatly improved the clinician's ability over the past decade to narrow the differential diagnosis. As a result, a likely diagnosis is determined in the majority of cases (14–16).

TABLE 2. METHODS TABLE

Category	Checklist Item	Yes	No
Panel assembly	Included experts from relevant clinical and nonclinical disciplines	X	
	Included individual who represents views of patients and society at large		X
	Included methodologist with appropriate expertise (documented expertise in development of conducting systematic reviews to identify the evidence base and development of evidence-based recommendations)		X
Literature review	Performed in collaboration with librarian		X
	Searched multiple electronic databases	X	
	Reviewed reference lists of retrieved articles	X	
Evidence synthesis	Applied prespecified inclusion and exclusion criteria	X	
	Evaluated studies for sources of bias	X	
	Explicitly summarized benefits and harms	X	
	Used PRISMA1 to report systematic review		X
	Used GRADE to describe quality of evidence		X
Generation of recommendations	Used GRADE to rate the strength of recommendations		X

Definition of abbreviations: GRADE = Grading of Recommendations Assessment, Development and Evaluation; PRISMA1 = Preferred Reporting Items for Systematic Reviews and Meta-Analyses.

The widespread use of HRCT to evaluate patients with ILD has reduced the need for invasive diagnostic procedures, although sampling is still performed to confirm or secure an accurate diagnosis. Diagnostic sampling is also performed when there is ongoing clinical suspicion of ILD despite a normal HRCT (i.e., occasionally patients whose HRCT was interpreted as normal have evidence of ILD on BAL or lung biopsy).

BAL is one sampling technique. It samples the cellular and acellular components of distal bronchioles and gas exchange units. BAL analysis is seldom diagnostic by itself, but BAL cell pattern results may support a diagnosis and/or narrow the differential diagnosis when considered in the context of the medical history (e.g., occupational and environmental exposures, drug ingestion, prior radiation therapy), physical examination (e.g., extrapulmonary abnormalities), and radiologic findings (e.g., HRCT findings). The usefulness of BAL cell profiles is the subject of ongoing debate and controversy because its findings are hampered by poor sensitivity and specificity (17). In addition, a normal BAL differential cell profile does not exclude the presence of microscopic abnormalities in lung tissue.

BAL is easily performed, well tolerated, and has been safely performed in acutely ill patients (e.g., patients with acute respiratory distress syndrome [ARDS]) (18, 19). It has rarely been reported to precipitate acute exacerbations or progression of ILD (20, 21). The safety of BAL is enhanced if a standard safety protocol is followed (22). BAL is contraindicated (relative) if the patient has cardiopulmonary instability or a severe hemorrhagic diathesis.

Alternative sampling techniques include transbronchial lung biopsy (TBLB) and surgical lung biopsy (SLB). TBLB is frequently diagnostic in certain forms of ILD (e.g., granulomatous lung disease), but it has some important limitations. The tissue retrieved is often inadequate or nondiagnostic, and the risk of complications is higher with TBLB than with BAL (23, 24). SLB is usually diagnostic, but the risk of complications (including death) is not negligible (25, 26).

There are no controlled clinical trials that have evaluated whether routine BAL in patients with ILD improves patient-important outcomes. However, the committee's collective clinical experience suggests that the results from BAL (cellular analysis, staining and culture for mycobacterial and fungal infection, cytopathology) may provide strong support or clues for a diagnosis or help narrow the differential diagnosis. The committee recognizes that there are insufficient data to confirm that BAL cell analysis is beneficial and, therefore, it is impossible to weigh the potential benefits against the risks, costs, and burdens of the procedure. For this reason, the committee feels that the decision to perform BAL cellular analyses should be determined on a case-by-case basis until there is published evidence that BAL significantly improves patient-important outcomes of patients with suspected or established ILD, and the ability to obtain reliable results is dependent upon the availability of local expertise in both BAL and ILD combined with adequate laboratory resources.

PERFORMING, HANDLING, AND PROCESSING BAL

BAL retrieves secretions that coat the apical surfaces of the bronchial and alveolar epithelium (diluted by the saline that is used to perform BAL). Many factors can affect the amount of fluid retrieved, as well as the cellular and acellular components of the retrieved secretions. Thus, technique is extremely important for obtaining appropriate BAL specimens and for the processing and analysis of the BAL fluid. The technical aspects of BAL are summarized in this section and described in depth in the online supplement.

Pre-Procedure Preparation

Patients with suspected ILD for whom the clinician is considering BAL should undergo routine clinical evaluation before the procedure. This evaluation, which includes inquiry and appropriate testing for bleeding tendencies, is intended to minimize the likelihood of procedure-related complications by identifying potential risk factors that can be corrected or mitigated in advance. Once it is confirmed that the patient is a suitable candidate for BAL, the procedure may be scheduled.

Recommendation 1. *For patients with suspected ILD in whom it has been decided that a BAL can be tolerated and will be performed, we suggest that the BAL target site be chosen on the basis of an HRCT performed before the procedure, rather than choosing a traditional BAL site (i.e., the right middle lobe or lingula). In our clinical practices, we perform the HRCT within 6 weeks of the BAL.*

HRCT can be useful for identifying target areas of the lung that are most likely to provide diagnostic specimens when sampling via BAL. Generally speaking, areas of alveolar ground glass opacity, more prominent nodular profusion, or fine reticulation are likely to provide optimal targets. Target areas as well as characteristics of parenchymal abnormalities may change with time and, therefore, the HRCT should not be performed too far in advance of the BAL procedure.

Although there are no controlled clinical trials that have compared whether BAL sites identified by HRCT yield more useful information than traditional BAL sites (i.e., easily accessible sites that provide a good volume of return such as the right middle lobe or lingula), some reports suggest that HRCT may be

useful for choosing a site of lavage. Garcia and coworkers (27) found significant interlobar variation in BAL cell differential counts for nonsarcoid ILD that was most divergent for BAL lymphocyte counts. In adition, Sterclova and colleagues (28) found good correlation of BAL lymphocytosis with higher alveolar HRCT scores, Clements and coworkers (29) found good correlation between ground-glass opacification and the intensity of alveolitis, and Agusti and colleagues (30) found significant correlation of BAL absolute cell numbers and differential cell count percentage with more extensive parenchymal change on HRCT for patients diagnosed with IPF. Ziora and coworkers (31) also found good correlation of higher BAL lymphocyte counts and lymphocyte subset changes from lung segments with greater parenchymal change as identified by HRCT. Finally, Rámila and colleagues (32) found high yield of BAL when HRCT was used to target areas of ground-glass opacity in patients without ILD with suspected infection but normal plain chest X-ray.

Therefore, we suggest performing the HRCT within 6 weeks of the procedure and using HRCT imaging to identify appropriate geographic areas for performing BAL. This suggestion is based upon the committee's collective clinical experience in using HRCT combined with BAL to evaluate patients with suspected ILD, plus the above accuracy studies that were limited by risk of bias, indirectness, and possible imprecision.

The BAL Procedure

During standard flexible bronchoscopy, the bronchoscope is placed in a wedge position within the selected bronchopulmonary segment. Normal saline (at room temperature) is instilled through the bronchoscope, with a total volume that is between 100 and 300 ml and divided into three to five aliquots. After the instillation of each aliquot, instilled saline is generally retrieved using a negative suction pressure less than 100 mm Hg. The negative suction pressure should be adjusted to avoid visible airway collapse. The minimal total volume retrieved should be greater than or equal to 5% of the instilled volume (optimal sampling retrieves $\geqslant$ 30%). If less than 5% of each instilled aliquot volume is recovered during the procedure due to retention of most of the fluid in the lung, the procedure should be aborted to avoid increased risk to the patient. A minimal volume of 5 ml of a pooled BAL sample is needed for BAL cellular analysis (the optimal volume is 10–20 ml); it is acceptable to pool all aliquots of the retrieved BAL fluid for routine analyses.

Occasionally, the gross appearance of the BAL fluid will provide diagnostic clues. For example, grossly bloody BAL fluid that returns with increasing intensity in sequential aliquots indicates acute diffuse alveolar hemorrhage, while grossly cloudy (i.e., milky or light brown-beige color) BAL fluid that returns with flocculent material that settles by gravity to the bottom of the container within 15 to 20 minutes of fluid retrieval is highly suggestive of pulmonary alveolar proteinosis (PAP).

Handling of the BAL Fluid

The BAL fluid should be collected in containers that do not promote cell adherence to container surfaces (e.g., silicone-coated glass or polypropylene or other plastics that are designed for suspension tissue culture). Its method of transport then depends upon how long it is anticipated that it will take to reach the analytical laboratory. BAL fluid can be transported "fresh" at room temperature if the laboratory is located within the same facility and there is minimal delay between BAL fluid retrieval and delivery to the laboratory. If delivery to the laboratory may take 30 to 60 minutes after retrieval, then specimens should be transported at 4°C (i.e., on ice). If a delivery time greater than 1 hour is anticipated, then transport in the original lavage saline is discouraged. Instead, the cells should be centrifuged at a speed that maintains cellular integrity (e.g., 250–300 $\times$ g for 10 min) and then resuspended in a nutrient-supplemented medium (e.g., MEM+25mM HEPES or RPMI 1640+25mM HEPES) and stored at 4°C, where they may remain for up to 24 hours. If a centrifuge is not available, MEM or RPMI could be added to the pooled lavage sample with subsequent storage at 4°C for up to 12 hours, but the sample should be transported to the laboratory as soon as possible and a prolonged interval between BAL fluid retrieval and laboratory processing is discouraged. BAL fluid should not be frozen or transported with dry ice.

Processing

Prompt processing of the BAL fluid or cell suspension once it reaches the laboratory provides optimal results. Labware should be used that does not promote cell adherence to container surfaces. Specimens with gross mucus can be strained through loose gauze, or small amounts of mucus can be dissolved with dithiothreitol, if necessary. The specimen should then be centrifuged at an appropriate speed, resuspended, and analyzed.

BAL fluid that is not going to be analyzed immediately should be centrifuged, the cell pellet resuspended in a nutrient-supplemented medium, and then refrigerated at 4°C for up to 24 hours. Cells that were already suspended in a nutrient-supplemented medium due to delayed transport can simply be refrigerated at 4°C. Specimens obtained more than 24 hours before are not suitable for analysis.

BAL CELLULAR ANALYSIS IN THE DIAGNOSIS OF SPECIFIC ILD

A variety of diagnostic studies may be performed on BAL fluid. In patients with suspected ILD, typical diagnostic studies are a differential cell count, microbiological studies (to screen for mycobacterial and fungal disease), and cytopathology.

Recommendation 2. *For patients with suspected ILD who undergo BAL, we recommend that a differential cell count be performed on the BAL fluid. This includes lymphocyte, neutrophil, eosinophil, and mast cell counts. The remaining sample may be used for microbiological, virological, and/or malignant cell cytology laboratory testing, if clinically indicated.*

The reason for routine cellular analysis whenever BAL is performed in a patient with suspected ILD is that identification or exclusion of a predominantly inflammatory cellular pattern (increased lymphocytes, eosinophils, and/or neutrophils) may support a specific type of ILD or help narrow the differential diagnosis, when considered in the context of the clinical and radiological findings. The notion that a prominence of specific nucleated inflammatory or immune cells in the BAL correlates with an increased likelihood of certain types of ILD is supported by numerous accuracy studies that are limited by risk of bias. These include pronounced BAL eosinophilia in eosinophilic pneumonia (33, 34) or drug reactions (35–37), and BAL lymphocytosis in sarcoidosis (38–41), hypersensitivity pneumonitis (41–43), pneumotoxic drug reactions (44, 45), or cellular NSIP (46, 47). An algorithm for using BAL cellular analysis in a patient with suspected ILD is suggested (Figure 1), and a separate algorithm for using BAL in patients with relatively acute onset of suspected ILD is also suggested (Figure 2).

Technique of BAL Cell Analyses

The cellular analysis should be performed within 1 hour if the BAL fluid is in nutrient-poor media (e.g., saline) or within 2 to 3 hours for optimal results if the BAL fluid is in a nutrient-supplemented

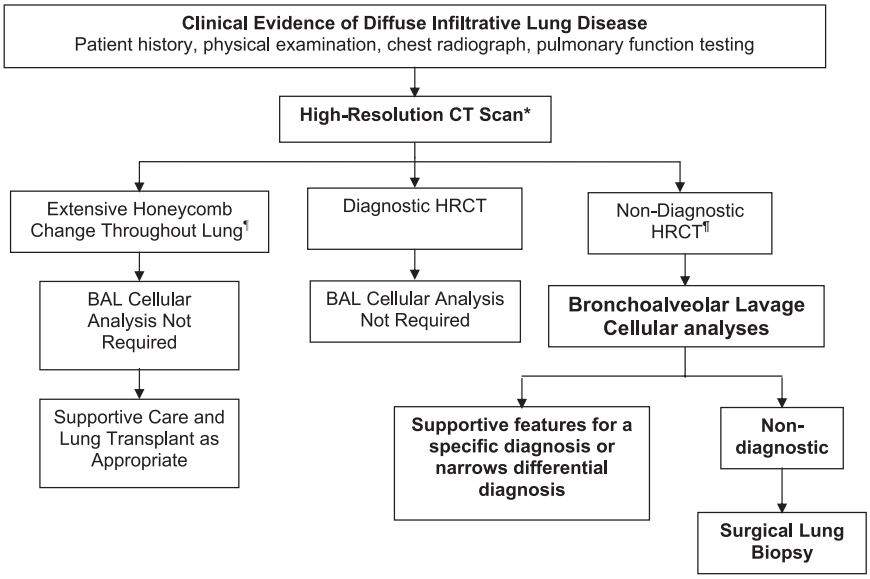

Figure 1. Algorithm for the clinical utility of bronchoalveolar lavage (BAL) cellular analysis in the evaluation of interstitial lung disease (ILD). *High-resolution computed tomography (HRCT) may not be necessary in all cases if routine chest radiographic findings are typical/diagnostic of specific ILD (e.g., sarcoidosis) and fit with other clinical data. Diseases that can be confidently diagnosed by HRCT in the appropriate clinical setting include sarcoidosis, usual interstitial pneumonia, and pulmonary Langerhans cell histiocytosis. ¶Infection and malignancy must be excluded as required by clinical features.

medium. The total cell count (nucleated immune cells) is usually obtained via a hemocytometer, and cell viability is determined by Trypan blue exclusion. Differential cell counts are performed via cytocentrifugation with staining (Wright-Giemsa or May-Grunwald-Giemsa) and enumeration of at least 400 cells. Representative photomicrographs of BAL cytospin preparations are shown in Figure 3. The presence and relative numbers of erythrocytes and epithelial cells should be noted. The presence of squamous epithelial cells suggests that BAL fluid is contaminated with upper airway secretions, and the presence of large numbers of bronchial epithelial cells suggests that the BAL may not have adequately sampled distal airspaces.

Excess BAL fluid can be stained and cultured for mycobacteria and fungi in the microbiology laboratory, as well as screened for neoplastic cells. These are important additional tests to consider because infections and diffuse neoplasms can masquerade as ILD or coexist with ILD.

Interpretation of BAL Differential Cell Counts

The ranges of differential cell counts that are considered normal and abnormal derive from several sources. Numerous investigators have published BAL immune cell profiles from cohorts of clinically normal volunteer subjects recruited in single-center studies (Table 3) (12, 48–53) and these reports have been used to define normal and abnormal differential cell counts. In addition, the multi-center BAL Cooperative Study (12) reported the differential cell counts in the BAL of normal subjects (including smokers or ex-smokers) compared with patients with ILD.

An increased number of nucleated immune cells and abnormal proportions of immune cell types may suggest or support specific types of ILD (Tables 1 and 4) in the absence of an infection. A mixed cellular pattern can be observed with any ILD; when mixed cellular patterns are observed, the dominant cell type may be the most consistent with a specific ILD diagnosis.

A BAL fluid cell differential count with greater than 15% lymphocytes, greater than 3% neutrophils, greater than 1% eosinophils, or greater than 0.5% mast cells indicates BAL lymphocytosis (i.e., a *lymphocytic cellular pattern*), BAL neutrophilia (i.e., a *neutrophilic cellular pattern*), BAL eosinophilia (i.e., an *eosinophilic cellular pattern*), or BAL mastocytosis, respectively. A lymphocyte differential count greater than or equal to 25% suggests granulomatous lung disease (e.g., sarcoidosis, HP,

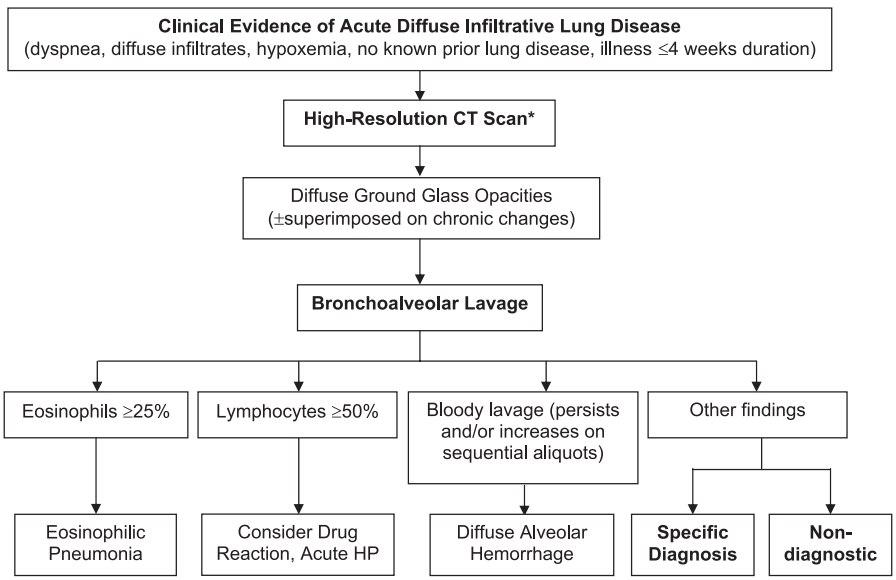

Figure 2. Algorithm for the BAL cellular analysis in the evaluation of acute onset ILD. *HRCT may not be required for every situation. Infection must be ruled out.

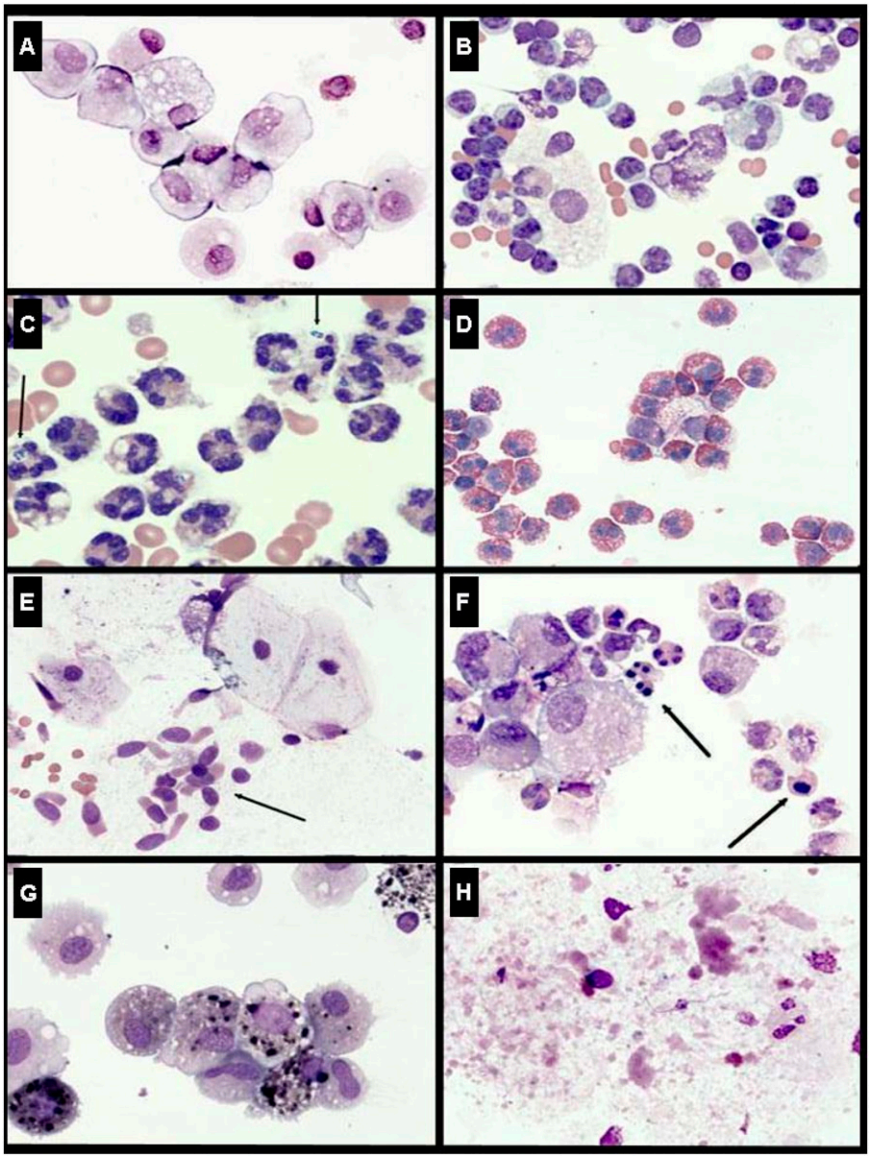

Figure 3. Photomicrographs of representative BAL cytospin preparations. (*A*) Predominance of alveolar macrophages in BAL from a normal subject. (*B*) BAL lymphocytosis. (*C*) BAL neutrophil predominance with intracellular bacteria (*arrows*). (*D*) BAL eosinophilia. (*E*) Unsatisfactory BAL specimen that shows squamous epithelial cells (large cells) and degenerating columnar epithelial cells (*arrow*). (*F*) BAL showing alveolar macrophages and degenerating neutrophils (*arrows*). (*G*) Hemosiderin-laden macrophages (diffuse alveolar hemorrhage). (*H*) Amorphous, predominantly acellular debris (pulmonary alveolar proteinosis).

NSIP, chronic beryllium disease, drug reaction, LIP, COP, or lymphoma), while a lymphocyte differential count greater than 50% is particularly suggestive of HP or cellular NSIP. An eosinophil differential count greater than or equal to 25% is virtually diagnostic of eosinophilic lung disease in the appropriate clinical setting. A neutrophil differential count greater

TABLE 3. VALUES FOR BAL TOTAL AND DIFFERENTIAL CELL COUNTS FOR ADULT NORMAL SUBJECTS (CYTOCENTRIFUGE METHOD)

Ref.	Age (*yr*)	N	Smoking Status	Site Lavaged	Volume (*ml*) and Aliquot Number	Total Volume Instilled (*ml*)	Cells/μl BAL Fluid*	AM%*	Lym%*	Neu%*	Eos%*
12	40 ± 2*	77	Never	RML	60 × 4	240	129 ± 20	85.2 ± 1.6	11.8 ± 1.1	1.6 ± 0.7	0.2 ± 0.1
	46 ± 2*	50	Ex	RML	60 × 4	240	139 ± 11	86.5 ± 1.4	11.5 ± 1.2	2.1 ± 0.5	0.5 ± 0.2
	43 ± 2*	64	Current	RML	60 × 4	240	418 ± 45	92.5 ± 1.0	5.2 ± 0.9	1.6 ± 0.2	0.6 ± 0.1
48	18-40	38	Never	RML	60 × 4	240	105 ± 7	89.5 ± 1.1	9.2 ± 1.1	1.0 ± 0.2	0.1 ± 0.1
	18-40	10	Never	LUL	60 × 4	240	113 ± 10	88.6 ± 2.0	9.9 ± 1.9	1.5 ± 0.3	0.1 ± 0.1
	65-78	30	Never	RML	60 × 4	240	158 ± 17	80.2 ± 2.1	15.1 ± 2.1	4.3 ± 0.9	0.5 ± 0.2
	18-40	23	Never	RML	40 × 4	160	103 ± 9	88.7 ± 1.2	9.4 ± 1.2	1.4 ± 0.1	0.3 ± 0.1
	18-40	20	Never	RUL	40 × 4	160	114 ± 13	88.9 ± 1.4	9.0 ± 1.4	1.9 ± 0.5	0.2 ± 0.1
49	33 ± 2*	18	Never	RML	20 × 10	200	108 ± 16	85.3 ± 2.1	12.6 ± 2.0	1.7 ± 0.1	0.4 ± 0.1
50	19-60	28	Non	RML	50 × 4	200	103 ± 15	89.8 ± 0.7	8.4 ± 0.7	1.3 ± 0.2	0.4 ± 0.1
51	20-36	78	Non	LUL	40 × 3	120	94 ± 5	95.1 ± 0.3	3.9 ± 0.03	0.7 ± 0.1	0.2 ± 0.1
52	18-41	19	Non	RML	50 × 6	300	116 ± 16	91 ± 0.6	8.3 ± 0.9	0.8 ± 0.6	0.3 ± 0.2
	20-49	13	Current	RML	50 × 6	300	358 ± 46	94 ± 1.0	5.4 ± 0.9	1.0 ± 0.3	0 ± 0
53	20-48	111	Never	RML or LUL	20 × 5	100	127 ± 9	93.2 ± 0.6	6.1 ± 0.5	0.5 ± 0.1	0.1 ± 0.04

Definition of abbreviations: AM = alveolar macrophage; BAL = bronchoalveolar lavage; Eos = eosinophils; Lym = lymphocytes; N = number of subjects; Neu = neutrophils; LUL = left upper lobe (lingula); RML = right middle lobe.

* Mean ± SE.

TABLE 4. CLINICAL PRESENTATION, HRCT AND BAL CELLULAR FINDINGS IN THE DIFFERENTIAL DIAGNOSIS OF ILD

Specific ILD	Usual Clinical Presentation	Usual HRCT Pattern	Usual BAL Cell Pattern	BAL Findings that Support Diagnosis
Acute interstitial pneumonitis (AIP)	Acute onset of dyspnea Diffuse consolidation on CXR	Diffuse, bilateral ground-glass attenuation with patchy airspace consolidation	↑↑ Neut	Prominent neutrophilia Infection and hemorrhage excluded
Idiopathic pulmonary fibrosis (UIP histopathology)	Gradual onset of dyspnea Older patient	Diffuse peripheral reticular pattern Honeycomb change Traction bronchiectasis	↑ AM, ↑ Neut ± ↑ Eos	Lack of prominent lymphocytosis or eosinophilia
Nonspecific interstitial pneumonia (NSIP)	Subacute onset of dyspnea	Ground-glass opacities or consolidation that mainly involves lower lung zones	↑ AM, ↑ Lymph, ↑ Neut	Typical BAL profile Hemorrhage, infection, and malignancy excluded
Desquamative interstitial pneumonia (DIP)	Smoking history	Bilateral ground-glass attenuation in lower lung zones	↑↑ AM (heavily pigmented)	Typical BAL profile Exclusion of hemorrhage, infection, malignancy
Respiratory bronchiolitis with interstitial lung disease (RB/ILD)	Smoking history	Poorly defined centrilobular nodules Ground-glass opacities Bronchial wall thickening	↑↑ AM (heavily pigmented)	Exclusion of hemorrhage, infection, malignancy
Cryptogenic organizing pneumonia (aka BOOP)	Subacute onset of cough Low-grade fever Shortness of breath Fatigue	Patchy, nonsegmental airspace consolildation that may be unilateral and peripheral (can be similar to EP)	↑ AM, Lymph, Neut ± ↑ Eos	Typical BAL profile Exclude hemorrhage, infection, malignancy
Eosinophilic pneumonia (EP)	Diffuse CXR infiltrates Rapid response to corticosteroids	Bilateral peripheral subpleural airspace consolidation	↑↑ Eos	Eos% ⩾ 25%
Lymphocytic interstitial pneumonia (LIP)	Reticular or reticulonodular pattern involving mostly lower lung zones Associated with underlying immunologic abnormalities	Bilateral ground-glass attenuation Scattered cysts	↑↑ Lymph	Elevated lymphocytes Exclusion of hemorrhage, infection, malignancy
Sarcoidosis	Bilateral hilar lymphadenopathy with normal physical examination Uveitis or erythema nodosum often present	Hilar/mediastinal adenopathy Nodules along bronchovascular bundles in mid/upper lung fields	↑↑ Lymph ± ↑ Neut	Lymphocytosis with typical clinical presentation and radiographic findings CD4/CD8 ratio ⩾ 3.5 increases specificity
Hypersensitivity pneumonitis (HP)	Acute or chronic presentation with exposure history	Acute: bilateral ground-glass opacities and poorly defined nodules Chronic: reticular fibrotic pattern ± honeycomb change and traction bronchiectasis ± ground-glass opacities	↑↑ Lymph, ↑ Neut "Foamy" AM cytoplasm ± Mast cells ± Plasma cells	Extreme lymphocytosis Plausible exposure history Exclude infection, hemorrhage, and malignancy
Diffuse alveolar hemorrhage (DAH)	Collagen vascular disease (especially lupus erythematosus) Acute dyspnea Hypoxemia	Patchy or diffuse areas of ground-glass attenuation Tend to be in dependent lung zones	Hemosiderin-laden Mac Free RBCs	Progressive increase in RBCs with sequential BAL aliquots Exclude infection, malignancy
Drug-induced pneumonitis	Drug ingestion history	Can appear similar to various ILD (UIP, NSIP, DAD, COP, HP, EP)	Variable ↑ Lymph, Neut, and/or Eos ± Mast cells	Hemorrhage (can be drug-induced), infection, and malignancy excluded
Scleroderma	Subacute dyspnea on exertion Dysphagia and gastroesophageal reflux Dermal fibrosis and telangiectasias	Reticular lines ± ground-glass attenuation	↑ Lymph, ↑ AM ± ↑ Neut, ± ↑Eos	Infection, hemorrhage, and malignancy excluded
Langerhans cell histiocytosis of lung (PLCH)	Smoker Subacute onset of dyspnea ± History of pneumothorax	Cysts and centrilobular nodules that can cavitate Most prominent in mid to upper lung zones	↑ AM ± ↑ Neut, ↑Eos, and/or ↑Lymph	CD1a-positive cells ⩾ 5% Infection, hemorrhage, and malignancy excluded
Pulmonary alveolar proteinosis (PAP)	Subacute onset of dyspnea	Alveolar filling pattern	Cloudy BAL fluid with milky to light brown appearance Debris settles out without centrifugation	PAS-positive amorphous debris Hemorrhage, infection, and malignancy excluded
Chronic beryllium disease (CBD)	Exposure history	Hilar lymphadenopathy Nodules along bronchovascular bundles	↑/↑↑ Lymph	Consistent cell pattern Positive lymphocyte proliferation test
Asbestosis	Exposure history Gradual onset of dyspnea	Irregular linear opacities with thickened interlobular septae that predominate in dorsal, subpleural areas Pleural plaques	↑/↑↑ Mac ↑ Neut, Eos, Lymph ↑ Mac and Eos with advanced disease	Presence of asbestosis bodies Infection, hemorrhage, and malignancy excluded
Silicosis	Exposure history Gradual onset of dyspnea	Dense, well-circumscribed nodules in upper and middle lung zones	↑ Mac ± ↑ Neut, Lymph	Silica-laden macrophages Infection, hemorrhage, and malignancy excluded
Lipoid pneumonia	History of mineral, vegetable, or animal oils (?constipation)	Extensive ground-glass opacities or consolidation with attenuation values between fat and water	Oily layer on surface of BAL fluid Vacuoles in Mac that stain positive for lipid	Lipid-laden macrophages Infection and hemorrhage excluded
Lymphangitic carcinoma	History of malignancy	Smooth or nodular thickening of bronchovascular bundles and interlobular septae and/or parenchymal nodules	Malignant cells on cytopathologic examination	Detection of malignant cells
Lymphangioleiomyomatosis (LAM)	Female sex Subacute onset of dyspnea ± History of pneumothorax	Randomly distributed, thin-walled cysts throughout lungs surrounded by normal parenchyma	No specific pattern	Infection, hemorrhage, and malignancy excluded
Bronchiolitis	Acute, subacute, or chronic presentation ± Connective tissue disease	Poorly defined centrilobular nodules Decreased attenuation and air trapping Tree-in-bud pattern	Variable ↑ in inflammatory cell populations	Infection, hemorrhage, and malignancy excluded
Pulmonary infection	Dyspnea and cough Fever and other constitutional symptoms Acute to subacute onset	Diverse patterns including alveolar filling pattern, consolidation, diffuse miliary infiltrates, "tree-in-bud," and diffuse ground-glass opacities	↑↑↑ Neut (suppurative, bacterial) ↑↑ Lymph (viral) ↑/↑↑ Eos (parasitic)	Positive stains on BAL sediment and/or positive cultures of plausible pathogen

Definition of abbreviations: AM = alveolar macrophage; BAL = bronchoalveolar lavage; CXR = chest radiograph; Eos = eosinophils; Lymph = lymphocytes; Neut = neutrophils; RBC = red blood cell.

than or equal to 50% strongly supports acute lung injury, aspiration pneumonia, or suppurative infection. Finally, a mast cell differential count greater than 1% combined with a lymphocyte differential count greater than 50% and a neutrophil count greater than 3% is suggestive of HP.

A predominance of macrophages containing smoking-related inclusions with no or minor increases in other cell types is compatible with smoking-related ILD, such as DIP, RBILD, or pulmonary Langerhans cell histiocytosis (PLCH). Additional tests to identify and count Langerhans cells in the appropriate clinical setting may be useful in narrowing the differential diagnosis. A predominance of hemosiderin-laden macrophages is suggestive of chronic or occult alveolar hemorrhage syndromes resulting in pulmonary hemosiderosis or diffuse alveolar damage.

A summary of the BAL immune cell pattern findings that correlate with specific ILDs is given in Tables 1 and 4. The role of BAL cellular analyses in the diagnosis and management of specific forms of ILD is discussed in depth in the online supplement.

Recommendation 3. *For patients with suspected ILD in whom BAL is performed, we suggest that lymphocyte subset analysis NOT be a routine component of BAL cellular analysis.*

Given the importance of promptly processing and analyzing the BAL specimen for optimal results, it is often asked whether a lymphocyte subset analysis should be routinely performed after BAL instead of waiting for the results of the differential cell count to decide. We believe that a lymphocyte subset analysis (by cytometry or immunocytochemistry) should not be performed routinely, but rather could be performed if a lymphocytic disease is suspected or the initial BAL cellular findings identify a lymphocytosis. This suggestion is based upon the committee's clinical experience that lymphocyte subset analysis is rarely helpful and potentially misleading in the absence of a clinically suspected lymphocytic disease or a lymphocytosis.

Many investigators have characterized lymphocyte subsets on the basis of T helper ($CD4^+$) versus T suppressor ($CD8^+$) phenotypes, and have found correlations of the $CD4^+/CD8^+$ T lymphocyte ratio with specific disease processes such as sarcoidosis (38, 54, 55) and hypersensitivity pneumonitis (42, 43, 56, 57). However, subsequent investigations have found that the $CD4^+/CD8^+$ ratio may not be significantly increased in a substantial number of patients with sarcoidosis (58, 59) or significantly decreased in a substantial proportion of patients with hypersensitivity pneumonitis (60, 61), and can change during the course of the disease process (55, 60). In addition, the BAL $CD4^+/CD8^+$ T lymphocyte ratio varies with age and may be significantly increased in normal subjects (62). These issues are discussed extensively in the portion of the online supplement that pertains to specific forms of ILD. However, in the case of sarcoidosis, the combination of BAL lymphocytosis combined with a considerably increased BAL $CD4^+/CD8^+$ lymphocyte ratio (e.g., $\geqslant 4$) may increase the confidence of a diagnosis of sarcoidosis if other clinical features and imaging are consistent with this diagnosis, and lymphocyte subset determinations may be performed at the discretion of the pulmonologist if such analysis can be reliably performed in the clinical laboratory and is considered to be clinically useful.

Finally, there are other tests that can be performed on BAL fluid on a case-by-case basis and may be helpful in specific clinical circumstances. Analysis by a cytopathologist is indicated if there are isolated cells that are suspicious for malignancy. Periodic Acid Schiff staining or Oil Red O staining may be helpful if pulmonary alveolar proteinosis or aspiration is suspected, respectively. Hemosiderin staining may be worthwhile if hemorrhage is suspected and/or the initial BAL raises the suspicion of hemosiderin-laden macrophages. Energy-dispersive electron microprobe analysis can be performed if inorganic dust bodies or particles within macrophages are suspected.

CONCLUSIONS AND FUTURE DIRECTIONS

The recommendations in these guidelines were informed largely by observational studies and the clinical observations of experts in the fields of BAL and ILD, since there is a paucity of evidence from controlled clinical trials related to the clinical utility of BAL cellular analysis. Acknowledging this limitation, these guidelines are intended to enhance the understanding of the clinical utility of BAL cellular analysis by pulmonologists and other clinicians and to assist them in the making appropriate clinical decisions when evaluating patients in whom a diagnosis of ILD is suspected. The recommendations in these guidelines can be used worldwide to standardize both the performance of BAL and the interpretation of BAL cellular analysis. It is hoped that these guidelines will provoke and facilitate future clinical studies in patients with suspected ILD, which investigate potential biomarkers in BAL that may predict prognosis and response to therapeutic interventions for ILD.

This statement was prepared by an *ad hoc* subcommittee of the ATS Assembly on Clinical Problems.

Members of the subcommittee:
KEITH C. MEYER, M.D., M.S. (*Co-Chair*)
GANESH RAGHU, M.D. (*Co-Chair*)
ROBERT P. BAUGHMAN, M.D.
KEVIN K. BROWN, M.D.
ULRICH COSTABEL, M.D.
ROLAND M. DU BOIS, M.D.
MARJOLEIN DRENT, M.D.
PATRICIA L. HASLAM, PH.D.
DONG SOON KIM, M.D.
SONOKO NAGAI, M.D.
PAOLA ROTTOLI, M.D.
CESARE SALTINI, M.D.
MOISÉS SELMAN, M.D.
CHARLIE STRANGE, M.D.
BRENT WOOD, PH.D.

Author Disclosures: K.C.M. reported consultancies with Bayer (up to $1,000), KaloBios, and Pharmaxis ($1,001–$5,000 each); he served on an advisory committee of Pharmaxis ($1,001–$5,000), and received research grants from Actelion, InterMune, Novartis, XDx ($10,001–$50,000 each), and Inspire ($5,000–$10,000). G.R. consulted with Amgen, Amira, Bayer, Boehringer Ingelheim, Celgene, Centocor, Genzyme, Gilead, Oncothyreon, Stromedix ($1–$9,999 each), and Actelion ($10,000–$49,999); he received lecture fees from Actelion ($1–$9,999) and a research grant from Actelion ($10,000–$49,999). R.P.B. consulted with Centocor (up to $1,000) and received research grants from Actelion, Celgene, and Centocor ($10,001–$50,000 each). K.K.B. consulted with Phillips (up to $1,000), Amgen, Celgene, Elan, Fibrogen, MondoBiotech, Pacific Therapeutics, Stromedix ($1,001–$5,000 each), Actelion, and Genzyme ($10,001–$50,000 each); he served on advisory committees of Boehringer Ingelheim, Centocor, Gilead, and Novartis ($5,001–$10,000 each) and received lecture fees from Biogen ($1,001–$5,000) and research grants from Actelion ($100,001+), Amgen, Genzyme, Gilead, and Novartis ($50,001–$100,000 each). U.C. consulted with Actelion ($1,001–$5,000), Bayer (up to $1,000), Boehringer Ingelheim, Centocor, and InterMune ($10,001–$50,000 each); he served on an advisory committee of Gilead ($1,001–$5,000) and received lecture fees from AstraZeneca and InterMune ($1,001–$5,000 each); he received research grants from Actelion, Centocor, Gilead ($10,001–$50,000 each), InterMune ($50,001–$100,000), and Boehringer Ingelheim ($100,001+). R.M.duB. consulted with Bayer and Cambridge Antibody Technology ($1,001–$5,000 each), and served on advisory committees of Actelion, Boehringer Ingelheim ($10,001–$50,000 each), Genzyme ($1,001–$5,000), and InterMune ($100,001+); he received lecture fees from Actelion ($5,001–$10,000), AstraZeneca, GlaxoSmithKline (up to $1,000 each), and InterMune ($1,001–$5,000). D.S.K. consulted with Boehringer Ingelheim ($5,001–$10,000) and received a research grant from Actelion ($10,001–$50,000). C.S. (Saltini) received lecture fees from Abbott, AstraZeneca, Boehringer Ingelheim, GlaxoSmithKline, and Pfizer ($1,001–$5,000 each). M.S. consulted with Boehringer Ingelheim ($5,001–$10,000). C.S. (Strange) consulted with Emphasys Medical ($5,001–$10,000) and served on advisory committees of Actelion ($1,001–$5,000), Arriva Pharmaceuticals (up to $1,000), AstraZeneca ($10,001–$50,000), Gilead ($5,001–$10,000), and Talecris ($1,001–$5,000); he received lecture fees from Actelion, AstraZeneca, Gilead, GlaxoSmithKline, and Talecris ($5,001–$10,000 each); he received research grants from Actelion, Emphasys Medical, InterMune ($100,001+ each), Aeris ($50,001–$100,000), Gilead, Pfizer ($10,001–$50,000 each), and Talecris ($50,001–$100,000) and royalties from UpToDate ($1,001–

$5,000). M.D., P.L.H., S.N., P.R., and B.W. reported no commercial interests or noncommercial, nongovernmental support relevant to subject matter.

NOTE FROM ATS DOCUMENTS EDITOR

The American Thoracic Society (ATS) is working toward the development of clinical practice guidelines that comply with the Institute of Medicine's (IOM) standards for clinical practice guidelines. This guideline was completed prior to the release of the standards and, therefore, was not required to comply with them. Nevertheless, the approach used to identify the evidence, appraise the evidence, and formulate recommendations for this guideline was more systematic and free from conflicts of interest than traditional guidelines. For these reasons, I am confident that this guideline provides accurate and thoughtful guidance to clinicians managing a patient with interstitial lung disease.

Kevin C. Wilson, M.D.
ATS Documents Editor

References

1. King TE Jr. Clinical advances in the diagnosis and therapy of the interstitial lung diseases. *Am J Respir Crit Care Med* 2005;172:268–279.
2. American Thoracic Society; European Respiratory Society. American Thoracic Society/European Respiratory Society International Multidisciplinary Consensus Classification of the Idiopathic Interstitial Pneumonias. *Am J Respir Crit Care Med* 2002;165:277–304.
3. Noth I, Martinez FJ. Recent advances in idiopathic pulmonary fibrosis. *Chest* 2007;132:637–650.
4. Raghu G, Collard HR, Egan JJ, Martinez FJ, Behr J, Brown KK, Colby TV, Cordier JF, Flaherty KR, Lasky JA, *et al*. An official ATS/ERS/JRS/ALAT statement: idiopathic pulmonary fibrosis: evidence-based guidelines for diagnosis and management. *Am J Respir Crit Care Med* 2011;183:788–824.
5. Flaherty KR, Travis WD, Colby TV, Toews GB, Kazerooni EA, Gross BH, Jain A, Strawderman RL, Flint A, Lynch JP, *et al*. Histopathologic variability in usual and nonspecific interstitial pneumonias. *Am J Respir Crit Care Med* 2001;164:1722–1727.
6. Papanikolaou IC, Drakopanagiotakis F, Polychronopoulos VS. Acute exacerbations of interstitial lung diseases. *Curr Opin Pulm Med* 2010;16:480–486.
7. Collard HR, Moore BB, Flaherty KR, Brown KK, Kaner RJ, King TE Jr, Lasky JA, Loyd JE, Noth I, Olman MA, *et al*. Acute exacerbations of idiopathic pulmonary fibrosis. *Am J Respir Crit Care Med* 2007;176:636–643.
8. Klech H, Pohl W, editors. Technical recommendations and guidelines for bronchoalveolar lavage (BAL): report of the European society of pneumology task group. *Eur Respir J* 1989;2:561–585.
9. Klech H, Hutter C, editors. Clinical guidelines and indications for bronchoalveolar lavage (BAL): report of the European society of pneumonolgy task group on BAL. *Eur Respir J* 1990;3:937–976.
10. Klech H, Hutter C, Costabel U, editors. Clinical guidelines and indications for bronchoalveolar lavage (BAL): report of the European society of pneumology task group on BAL. *Eur Respir Rev* 1992;2:47–127.
11. Haslam PL, Baughman RP. Report of ERS task force: guidelines for measurement of acellular components and standardization of BAL. *Eur Respir J* 1999;14:245–248.
12. The BAL Co-operative Group Steering Committee. Bronchoalveolar lavage constituents in healthy individuals, idiopathic pulmonary fibrosis, and selected comparison groups. *Am Rev Respir Dis* 1990;141:S169–S202.
14. Müller NL, Fraser RS, Lee KS, Johkoh T. Diseases of the lung. Philadelphia: Lippincott, Williams & Wilkins; 2003.
15. Collins J. CT signs and patterns of lung disease. *Radiol Clin North Am* 2001;39:1115–1135.
16. Kanne JP. Interstitial lung disease (ILD): imaging finding, and the role of imaging in the evaluating the patient with known or suspected ILD. *Semin Roentgenol* 2010;45:3.
17. Wells AU. The clinical utility of bronchoalveolar lavage in diffuse parenchymal lung disease. *Eur Respir Rev* 2010;19:237–241.
18. Steinberg KP, Mitchell DR, Maunder RJ, Milberg JA, Whitcomb ME, Hudson LD. Safety of bronchoalveolar lavage in patients with adult respiratory distress syndrome. *Am Rev Respir Dis* 1993;148:556–561.
19. Hertz MI, Woodward ME, Gross CR, Swart M, Marcy TW, Bitterman PB. Safety of bronchoalveolar lavage in the critically ill, mechanically ventilated patient. *Crit Care Med* 1991;19:1526–1532.
20. Hiwatari N, Shimura S, Takishima T, Shirato K. Bronchoalveolar lavage as a possible cause of acute exacerbation in idiopathic pulmonary fibrosis patients. *Tohoku J Exp Med* 1994;174:379–386.
21. Kim DS, Park JH, Park BK, Lee JS, Nicholson AG, Colby T. Acute exacerbation of idiopathic pulmonary fibrosis: frequency and clinical features. *Eur Respir J* 2006;27:143–150.
22. Dransfield MT, Garver RI, Weill D. Standardized guidelines for surveillance bronchoscopy reduce complications in lung transplant recipients. *J Heart Lung Transplant* 2004;23:110–114.
23. Ahmad M, Livingston DR, Golish JA, Mehta AC, Wiedemann HP. The safety of outpatient transbronchial biopsy. *Chest* 1986;90:403–405.
24. Simpson FG, Arnold AG, Purvis A, Belfield PW, Muers MF, Cooke NJ. Postal survey of bronchoscopic practice by physicians in the UK. *Thorax* 1986;41:311–317.
25. Kramer MR, Berkman N, Mintz B, Godfrey S, Saute M, Amir G. The role of open lung biopsy in the management and outcome of patients with diffuse lung disease. *Ann Thorac Surg* 1998;65:198–202.
26. Utz JP, Ryu JH, Douglas WW, Hartman TE, Tazelaar HD, Myers JL, Allen MS, Schroeder DR. High short-term mortality following lung biopsy for usual interstitial pneumonia. *Eur Respir J* 2001;17:175–179.
27. Garcia JG, Wolven RG, Garcia PL, Keogh BA. Assessment of interlobar variation of bronchoalveolar lavage cellular differentials in interstitial lung diseases. *Am Rev Respir Dis* 1986;133:444–449.
28. Sterclova M, Vasakova M, Dutka J, Kalanin J. Extrinsic allergic alveolitis: comparative study of the bronchoalveolar lavage profiles and radiological presentation. *Postgrad Med J* 2006;82:598–601.
29. Clements PJ, Goldin JG, Kleerup EC, Furst DE, Elashoff RM, Tashkin DP, Roth MD. Regional differences in bronchoalveolar lavage and thoracic high-resolution computed tomography results in dyspneic patients with systemic sclerosis. *Arthritis Rheum* 2004;50:1909–1917.
30. Agusti C, Xaubet A, Luburich P, Ayuso MC, Roca J, Rodriguez-Roisin R. Computed tomography-guided bronchoalveolar lavage in idiopathic pulmonary fibrosis. *Thorax* 1996;51:841–845.
31. Ziora D, Grzanka P, Mazur B, Niepsuj G, Oklek K. BAL from two different lung segments indicated by high resolution computed tomography (HRCT) in patients with sarcoidosis. I. Evaluation of alveolitis homogeneity and estimation of HRCT usefulness in selection of lung region for BAL [in Polish]. *Pneumonol Alergol Pol* 1999;67:422–434.
32. Rámila E, Sureda A, Martino R, Santamaría A, Franquet T, Puzo C, Montesinos J, Perea G, Sierra J. Bronchoscopy guided by high-resolution computed tomography for the diagnosis of pulmonary infections in patients with hematologic malignancies and normal plain chest X-ray. *Haematologica* 2000;85:961–966.
33. Allen JN, Davis WB, Pacht ER. Diagnostic significance of increased bronchoalveolar lavage fluid eosinophils. *Am Rev Respir Dis* 1990;142:642–647.
34. Pope-Harman AL, Davis WB, Allen ED, Christoforidis AJ, Allen JN. Acute eosinophilic pneumonia: a summary of 15 cases and review of the literature. *Medicine (Baltimore)* 1996;75:334–342.
35. Sitbon O, Bidel N, Dussopt C, Azarian R, Braud ML, Lebargy F, Fourme T, de Blay F, Piard F, Camus P. Minocycline pneumonitis and eosinophilia: a report on eight patients. *Arch Intern Med* 1994;154:1633–1640.
36. Costabel U, Uzaslan E, Guzman J. Bronchoalveolar lavage in drug-induced lung disease. *Clin Chest Med* 2004;25:25–35.
37. Poulter LW, Rossi GA, Bjermer L, Costabel U, Israel-Biet D, Klech H, Pohl W, Velluti G. The value of bronchoalveolar lavage in the diagnosis and prognosis of sarcoidosis. *Eur Respir J* 1990;3:943–944.
38. Winterbauer RH, Lammert J, Selland M, Wu R, Corley D, Springmeyer SC. Bronchoalveolar lavage cell populations in the diagnosis of sarcoidosis. *Chest* 1993;104:352–361.

39. Keogh BA, Hunninghake GW, Line BR, Crystal RG. The alveolitis of pulmonary sarcoidosis: evaluation of natural history and alveolitis-dependent changes in lung function. *Am Rev Respir Dis* 1983;128: 256–265.
40. Laviolette M, La Forge J, Tennina S, Boulet LP. Prognostic value of bronchoalveolar lavage lymphocyte count in recently diagnosed pulmonary sarcoidosis. *Chest* 1991;100:380–384.
41. Ratjen F, Costabel U, Griese M, Paul K. Bronchoalveolar lavage fluid findings in children with hypersensitivity pneumonitis. *Eur Respir J* 2003;21:144–148.
42. Yoshizawa Y, Ohtani Y, Hayakawa H, Sato A, Suga M, Ando M. Chronic hypersensitivity pneumonitis in Japan: a nationwide epidemiologic survey. *J Allergy Clin Immunol* 1999;103:315–320.
43. Pardo A, Smith KM, Abrams J, Coffman R, Bustos M, McClanahan TK, Grein J, Murphy EE, Zlotnik A, Selman M. CCL18/DC-CK-1/PARC up-regulation in hypersensitivity pneumonitis. *J Leukoc Biol* 2001;70: 610–616.
44. Schnabel A, Richter C, Bauerfeind S, Gross WL. Bronchoalveolar lavage cell profile in methotrexate induced pneumonitis. *Thorax* 1997;52:377–379.
45. Akoun GM, Cadranel JL, Rosenow EC III, Milleron BJ. Bronchoalveolar lavage cell data in drug-induced pneumonitis. *Allerg Immunol (Paris)* 1991;23:245–252.
46. Shimizu S, Yoshinouchi T, Ohtsuki Y, Fujita J, Sugiura Y, Banno S, Yamadori I, Eimoto T, Ueda R. The appearance of s-100 protein-positive dendritic cells and the distribution of lymphocyte subsets in idiopathic nonspecific interstitial pneumonia. *Respir Med* 2002;96:770–776.
47. Ryu YJ, Chung MP, Han J, Kim TS, Lee KS, Chun EM, Kyung SY, Jeong SH, Colby TV, Kim H, *et al*. Bronchoalveolar lavage in fibrotic idiopathic interstitial pneumonias. *Respir Med* 2007;101:655–660.
48. Meyer K. Bronchoalveolar lavage in the diagnosis and management of interstitial lung disease. *Clin Pulm Med* 2007;141:148–156.
49. Sutinen S, Riska H, Backman R, Sutinen SH, Froseth B. Alveolar lavage fluid (ALF) of normal volunteer subjects: cytologic, immunocytochemical, and biochemical reference values. *Respir Med* 1995;89:85–92.
50. Drent M, Wagenaar S, van Velzen-Blad H, Mulder PG, Hoogsteden HC, van den Bosch JM. Relationship between plasma cell levels and profile of bronchoalveolar lavage fluid in patients with subacute extrinsic allergic alveolitis. *Thorax* 1993;48:835–839.
51. Ettensohn DB, Jankowski MJ, Duncan PG, Lalor PA. Bronchoalveolar lavage in the normal volunteer subject: I. Technical aspects and intersubject variability. *Chest* 1988;94:275–280.
52. Barbers RG, Gong H Jr, Tashkin DP, Oishi J, Wallace JM. Differential examination of bronchoalveolar lavage cells in tobacco cigarette and marijuana smokers. *Am Rev Respir Dis* 1987;135:1271–1275.
53. Merchant RK, Schwartz DA, Helmers RA, Dayton CS, Hunninghake GW. Bronchoalveolar lavage cellularity: the distribution in normal volunteers. *Am Rev Respir Dis* 1992;146:448–453.
54. Welker L, Jorres RA, Costabel U, Magnussen H. Predictive value of BAL cell differentials in the diagnosis of interstitial lung diseases. *Eur Respir J* 2004;24:1000–1006.
55. Drent M, van Velzen-Blad H, Diamant M, Hoogsteden HC, van den Bosch JM. Relationship between presentation of sarcoidosis and T lymphocyte profile: a study in bronchoalveolar lavage fluid. *Chest* 1993;104:795–800.
56. Trentin L, Migone N, Zambello R, di Celle PF, Aina F, Feruglio C, Bulian P, Masciarelli M, Agostini C, Cipriani A, *et al*. Mechanisms accounting for lymphocytic alveolitis in hypersensitivity pneumonitis. *J Immunol* 1990;145:2147–2154.
57. Depierre A, Dalphin JC, Pernet D, Dubiez A, Faucompre C, Breton JL. Epidemiological study of farmer's lung in five districts of the French Doubs province. *Thorax* 1988;43:429–435.
58. Kantrow SP, Meyer KC, Kidd P, Raghu G. The CD4/CD8 ratio in BAL fluid is highly variable in sarcoidosis. *Eur Respir J* 1997;10:2716–2721.
59. Danila E, Norkūniene J, Jurgauskiene L, Malickaite R. Diagnostic role of BAL fluid CD4/CD8 ratio in different radiographic and clinical forms of pulmonary sarcoidosis. *Clin Respir J*. 2009;3:214–221.
60. Barrera L, Mendoza F, Zuñiga J, Estrada A, Zamora AC, Melendro EI, Ramírez R, Pardo A, Selman M. Functional diversity of T-cell subpopulations in subacute and chronic hypersensitivity pneumonitis. *Am J Respir Crit Care Med* 2008;177:44–55.
61. Morell F, Roger A, Reyes L, Cruz MJ, Murio C, Muñoz X. Bird fancier's lung: a series of 86 patients. *Medicine (Baltimore)* 2008;87:110–130.
62. Meyer KC, Soergel P. Bronchoalveolar lymphocyte phenotypes change in the normal aging human lung. *Thorax* 1999;54:697–700.